

# Maxillary Second Molar with Fused Root and Six Canals- A Case Report

MITTHRA SURESH<sup>1</sup>, KITTAPPA KARTHIKEYAN<sup>2</sup>, SEKAR MAHALAXMI<sup>3</sup>

## ABSTRACT

One of the known aberrations in root canal morphology of maxillary second permanent molars is the presence of collateral mesiobuccal canals. This case report describes the endodontic management of a maxillary second molar that had a single fused root with six canals that was successfully managed with the aid of dental operating microscope. Six canal orifices were located namely MB1 (Mesiobuccal), MB2, MB3, DB1 (Distobuccal), DB2 and palatal. During the cleaning and shaping, instrument separation occurred at the apical third of the palatal canal which was removed with ultrasonics. After cleaning and shaping, the canals were obturated with resin sealer and laterally condensed gutta-percha. The patient was recalled for periodic review. After two years of follow up the patient remained asymptomatic. Cone Beam Computed Tomography (CBCT) evaluation revealed satisfactory periapical status.

**Keywords:** Additional canals, Cone beam computed tomography, Dental operating microscope, Endodontic management, Root canal morphology

## CASE REPORT

A 20-year-old female patient reported with pain in the right upper back tooth region. The medical history was noncontributory. Clinical examination revealed a fractured class II temporary restoration in the permanent maxillary right second molar, with tenderness on percussion. On visualization of the pre-operative radiograph, a coronal radiopacity suggestive of the restorative material approximating the pulp with widening of the periodontal ligament space was observed in the specified tooth. On examination of the intra-oral periapical radiograph morphological variation of the root canal anatomy was not evident; however it revealed the presence of a fused root [Table/Fig-1a]. Based on clinical and radiographic evaluation, a diagnosis of symptomatic irreversible pulpitis with apical periodontitis in tooth number 17 (maxillary right second molar) was made.

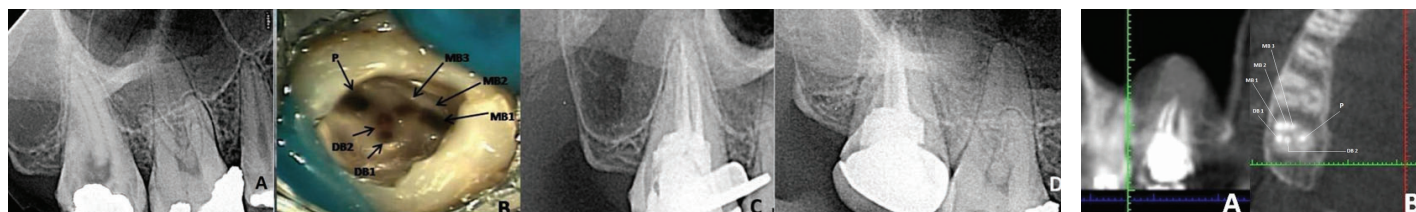
The tooth was anaesthetized; and removal of the temporary restoration revealed secondary caries beneath the restoration. There was extensive loss of the coronal tooth structure, hence pre-endodontic composite build up was done and the tooth was isolated under rubber dam. The access cavity preparation revealed the orifices of four canals: two mesiobuccal, one distobuccal and one palatal. Since both mesiobuccal canals were far apart, anticipating an additional canal, the line between the two mesiobuccal canals was troughed with ultrasonic tip. This revealed another orifice midway between two mesiobuccal canals. Further probing of the groove along distobuccal canal revealed the presence of second distobuccal canal. The final access cavity revealed the presence of six canal orifices (three mesiobuccal, two distobuccal and one palatal) which was confirmed by visualization under the dental operating microscope (Seiler Revelation<sup>®</sup>, Seiler Instruments, St Louis, Missouri, USA) [Table/Fig-1b] [1].

Working length was determined using apex locator (Root ZX; Morita, Tokyo, Japan) and confirmed with radiograph. Cleaning and shaping was carried out using stainless steel K- files (Mani, Tochigi, Japan) till 2% 20 size followed by rotary ProTapers (Dentsply, Maillefer) till F2 size. Irrigation was done using 3% sodium hypochlorite solution throughout the procedure. During canal preparation, approximately 12mm length of ProTaper S1 rotary file separated at the apical portion of the palatal canal. The separated instrument was removed using ultrasonics under the operating microscope.

After completion of the canal preparation, calcium hydroxide (Apexal, Ivoclar, Vivadent, AG FL – 9494 Schaan/Liechtenstein) intra canal medicament was given and the tooth was temporized with Cavit G (3M, ESPE, Seefeld, Germany). After one week, the canals were obturated with lateral condensation technique using AH plus resin sealer (Maillefer, Dentsply, Konstanz, Germany) & guttapercha points (Dentsply, Maillefer) [Table/Fig-1c]. This was followed by composite resin core build-up and a post endodontic metal ceramic restoration. The patient was recalled for periodic review. After two years of follow up [Table/Fig-1d] the patient remained asymptomatic. A CBCT evaluation at two years follow up revealed satisfactory periapical status [Table/Fig-2] [1].

## DISCUSSION

Maxillary molars have three roots (96.2%) two buccal and one palatal [2]. The possible variations in the external root morphology in these teeth are extra root, fused roots or a single conical root. A tooth with a single conical root usually has a single large canal [3]; however, teeth with fused roots will definitely have more than one canal. Due to the extensive use of magnification and illumination aids, the incidence of extra roots and/or canals in the maxillary molars and their management has been extensively discussed in the literature [2-5].



**[Table/Fig-1]:** (a) Pre-operative radiograph; (b) Photograph showing the access cavity with six canal orifices in tooth 17 (maxillary right second molar); (c) Immediate post-operative radiograph; (d) Radiograph at two years follow up. **[Table/Fig-2]:** CBCT images at two years follow up.

Author name	Year	No. of canals	No. of teeth studied	Root Configuration	Canal anatomy details
Fahid & Taintor [7]	1988	5	1	4 roots	2 separate DB roots with a separate apex
Christi WH et al., [12]	1991	4	16 First and second molars	4 roots	2 palatal roots
Peikoff MD al., [8]	1996	3,4,2,1	520	3,2,1,4	3 separate roots with 3 canals, 3 separate roots with 4 canals, 2 roots each with a single canal, 1 root with 1 canal, 4 roots with 4 canals
Zmener & Peirano [16]	1998	4	1	4 roots	Three separated buccal roots
Fava LRG et al., [3]	2000	1	4	1 root	1 root with a single canal
Alani AH et al., [6]	2003	4	2	4 roots	4 roots with 4 canals
Junior BP et al., [9]	2007	6	1	3 roots	Three palatal root canals with a single palatal root
Kottoor J et al., [1]	2010	5	1	5 roots	5 roots with 5 root canals MB1, MB2, DB, DP(distopalatal) and palatal
Zhao J et al., [13]	2011	5	1	4 roots	Three separate root canals (MB1, MB2, MB3) in a single MB root
Patel S & Patel P [14]	2012	4	2	4 roots	Two separate palatal roots
Brito M Jr et al., [15]	2013	5	1	5 roots	Three buccal roots (MB, mid-buccal, DB)
Zhang Q et al., [11]	2014	3,4	187	3, 4 roots	Three separate roots (57.7%) and fused roots (42.5%). Canal merging between: MB, DB canals (16 teeth)/ MB, DB/ P canals (9 teeth)
Zeng C et al., [10]	2016	5	1	4 roots	MB root (C shaped) with 2 canals, 2 fused DB roots with 2 separate canals

**[Table/Fig-3]:** Some clinical studies and case reports of maxillary second molars with unusual canal morphology.

So far the number of canals in maxillary second molar have been reported to vary from 1-6 [4-10]. Moreover occurrence of fused roots is more prevalent in maxillary second molars (42%) [10,11]. Morphological variations of the maxillary second molar in the number of roots and root canal anatomy reported by various authors has been summarized [Table/Fig-3] [1,3,6-16].

On comparison of the maxillary first, second and third molars, a considerable difference exists in between the degree of root separation and fusion. According to Percora and his researchers, among a total of 744 maxillary first, second and third molars observed, complete separation of all three roots was 86.4%, 75.9%, 18.8 % respectively. Whereas fusion of all three roots and fusion of only the buccal roots was 0.07%, 1.8%, 17.4% and 7.9%, 20.4%, 28.9% respectively [17].

The incidence of six canals in a maxillary second molar with a single root/fused roots has not been reported in the literature so far. This article presents one such case report. The canal configuration reveals one palatal, 3 mesiobuccal and 2 distobuccal canals. In the present case the preoperative radiograph showed the presence of conical root morphology, which can be single root or fused roots. Preoperative Radio Visio Graphy (RVG) images in different angulations did not give sufficient information about the number of root canals. The extra canals were identified by visualizing the bleeding spots under magnification, troughing with ultrasonic

tips and probing with DG 16 explorer. Working length radiograph confirmed the presence of six canals.

Separation of endodontic files is a common incident during root canal treatment that prevents efficient cleaning and shaping of the root canal and may result in treatment failure [18]. During the canal preparation, rotary ProTaper instrument (S1) separated in the apical third of the palatal canal. This was removed by using ultrasonic equipment under high magnification.

Although CBCT is a diagnostic tool used for evaluating the root canal morphology [10,13,15], it was not used preoperatively since in the present case the initial radiographs indicated the presence of fused roots, but did not show any variation in the canal anatomy. As per the guidelines set by the American Association of Endodontists, CBCT is advocated only when conventional radiographs or other imaging techniques fail to disclose important diagnostic and clinical information. However, a postoperative CBCT analysis was performed when the patient reported for her second year follow up to confirm the root and canal morphology and to evaluate the periapical status [Table/Fig-2].

## CONCLUSION

This unique case report gives an insight to yet another variation in the root and canal morphology of a maxillary second molar. Extra canals and/or roots can occur in any tooth and a tooth with single root may not always contain one canal. This is the first report that describes the endodontic management of a maxillary second molar with fused roots and six canals. Failure to locate and treat additional canals can adversely affect the outcome of endodontic therapy. Various adjuncts such as dental operating microscope and CBCT enable the clinician to perform endodontic treatment in a more precise and predictable manner.

## ACKNOWLEDGEMENTS

I affirm that I/We have no financial affiliation (e.g., employment, direct payment, stock holdings, retainers, consultancies, patent licensing arrangements or honoraria), or involvement with any commercial organization with direct financial interest in the subject or materials discussed in this manuscript, nor have any such arrangements existed in the past three years. Any other potential conflict of interest is disclosed.

## REFERENCES

- [1] Kottoor J, Hemamalathi S, Sudha R, Velmurugan N. Maxillary second molar with 5 roots and 5 canals evaluated using cone beam computerized tomography: a case report. *Oral Surg Oral Med Oral Pathol Oral Radiol Endod.* 2010;109:e162-65.
- [2] Cleghorn BM, Christie WH, Dong CSC. Root and root canal morphology of the human permanent maxillary first molar: a literature review. *J Endod.* 2006;32:813-21.
- [3] Fava LRG, Weinfeld I, Fabri FP, Pais CR. Four second molars with single roots and single canals in the same patient. *Int Endod J.* 2000;33:138-42.
- [4] Karthikeyan K, Mahalaxmi S. New nomenclature for extra canals based on four reported cases of maxillary first molars with six canals. *J Endod.* 2010;36:1073-78.
- [5] Barbizam JVB, Riberiro RG, Filho MT. Unusual anatomy of permanent maxillary molars. *J Endod.* 2004;30:668-71.
- [6] Alani AH. Endodontic treatment of bilaterally occurring 4-rooted maxillary second molars: case report. *J Can Dent Assoc.* 2003;69:733-35.
- [7] Fahid A, Taintor JF. Maxillary second molar with three buccal roots. *J Endod.* 1988;14:181-83.
- [8] Peikoff MD, Christie WH, Fogel HM. The maxillary second molar: variations in the number of root and canals. *Int Endod J.* 1996;29:365-69.
- [9] Junior BP, Teixeira CDS, Silva RG, Vansan LP, Neto MDS. Treatment of a second maxillary molar with six canals. *Aust Endod J.* 2007;33:42-45.
- [10] Zeng C, Shen Y, Guan X, Wang X, Fan M, Li Y. Rare root canal configuration of bilateral maxillary second molars using cone beam computed tomographic scanning. *J Endod.* 2016;42:673-77.
- [11] Zhang Q, Chen H, Fan B, Fan W, Gutmann JL. Root and root canal morphology in maxillary second molar with fused root from a native Chinese population. *J Endod.* 2014;40:871-75.
- [12] Christie WH, Peikoff MD, Fogel HM. Maxillary molars with two palatal roots: a retrospective clinical study. *J Endod.* 1991;17:80-84.

- [13] Zhao J, Li Y, Yang ZW, Wang W, Meng Y. Three-dimensional computed topography analysis of a patient with an unusual anatomy of the maxillary second and third molars. *Int J Oral Sci.* 2011;3:225-28.
- [14] Patel S, Patel P. Endodontic management of maxillary second molar with two palatal roots: a report of two cases. *Case Rep Dent.* 2012;2012:590406.
- [15] Brito M Jr, Moreira G Jr, Normanha JA, Faria-e-Silva AL, Camilo CC, Savioli RN, et al. Midbuccal canals of maxillary molars evaluated by cone beam computed tomography: endodontic management of two cases. *Braz Dent J.* 2013;24:575-79.
- [16] Zmener O, Peirano A. Endodontic therapy in a maxillary second molar with three buccal roots. *J Endod.* 1998;24:376-77.
- [17] Pecora JD, woelfel JB, Neto MDS. Morphologic study of the maxillary molars. *Braz Dent J.* 1991;2:45-50.
- [18] Madarati AA, Qualtrough AJE, Watts DC. A microcomputed tomography scanning study of root canal space: changes after the ultrasonic removal of fractured files. *J Endod.* 2009;35:125-28.

**PARTICULARS OF CONTRIBUTORS:**

1. Reader, Department of Conservative Dentistry and Endodontics, Sree Balaji Dental College and Hospital, Bharath University, Chennai, Tamil Nadu, India.
2. Reader, Department of Conservative Dentistry and Endodontics, SRM Dental College and Hospital, SRM University, Ramapuram, Chennai, Tamil Nadu, India.
3. Professor and Head, Department of Conservative Dentistry and Endodontics, SRM Dental College and Hospital, SRM University, Ramapuram, Chennai, Tamil Nadu, India.

**NAME, ADDRESS, E-MAIL ID OF THE CORRESPONDING AUTHOR:**

Dr. Kittappa Karthikeyan,  
Reader, Department of Conservative Dentistry and Endodontics, SRM Dental College and Hospital,  
SRM University, Ramapuram, Chennai, Tamil Nadu, India.  
Email: dockarthicck@yahoo.com

**FINANCIAL OR OTHER COMPETING INTERESTS:** None.

Date of Submission: **Oct 23, 2016**  
Date of Peer Review: **Dec 10, 2016**  
Date of Acceptance: **Jan 13, 2017**  
Date of Publishing: **Apr 01, 2017**